

Successful Treatment of Acquired Amegakaryocytic Thrombocytopenia (AAT) with Cyclosporine and Eltrombopag: A Case Report

Pardal de la Mano E¹, Martín-Sánchez G², López López RM¹, Fernández Gálan MA¹, González Hurtado JA¹ and Martín-Núñez G¹

¹Department of Hematology, Hospital Virgen del Puerto, Plasencia, Spain

²Department of Hematology, Hospital Universitario Marqués de Valdecilla, Santander, Spain

*Corresponding author: Pardal de la Mano E, Department of Hematology, Hospital Virgen del Puerto, Avd Valcorchero s/n 10,600, Plasencia, Spain, Fax: 00 34 927 42 54 32, Tel: 00349274580000, E-mail: emilia.pardal@salud-juntaex.es

Citation: Pardal de la Mano E, Martín-Sánchez G, López López RM, Fernández Gálan MA, González Hurtado JA, *et al.* (2018) Successful Treatment of Acquired Amegakaryocytic Thrombocytopenia (AAT) with Cyclosporine and Eltrombopag: A Case Report. *J Hematol Blood Disord* 4(1): 101

Abstract

Acquired amegakaryocytic thrombocytopenia is an unusual hematological disorder characterized by severe thrombocytopenia in association with a marked decrease, or the absence, of megakaryocytes in bone marrow. Its pathogenesis is not well understood and its clinical course is variable. Several treatments have been used, producing different responses. We present a case that was successfully treated with a calcineurin inhibitor combined with a thrombopoiesis-stimulating agent.

Keywords: Amegakaryocytic Thrombocytopenia; Eltrombopag; Aplastic Anemia; Cyclosporine

Background

Acquired amegakaryocytic thrombocytopenia (AAT) is an unusual hematological disorder characterized by severe thrombocytopenia in association with a marked decrease, or the absence, of megakaryocytes in bone marrow (BM) in the presence of otherwise normal hematopoiesis [1]. Its pathogenesis is not well understood, but various causes have been proposed, including exposure to occupational toxic agents, and autoimmune and viral diseases [2-4]. Its clinical course is variable, with long remitting and relapsing periods despite treatment or, in other cases, evolution to aplasia, acute myeloid leukemia, or myelodysplastic syndrome [5,6]. AAT is often refractory to steroids, gamma globulins, and other immunosuppressive treatments. However, responses to aggressive therapies with calcineurin inhibitors and thrombopoiesis-stimulating agents (TSAs) have been reported [7-9]. Here we describe a case treated with cyclosporine (CsA) and eltrombopag (EPAG).

Case report

A 58-year-old Caucasian man was admitted to the hospital emergency room with a ten-day history of bleeding, bruising, ecchymosis, and epistaxis, with slight fatigue but no fever. He had a medical history of chronic alcoholic liver disease, mild portal hypertension, 15 cm splenomegaly (determined by ultrasound) and a baseline platelet count of around $130 \times 10^9/L$. Six years before being admitted to hospital, he had suffered a traumatic injury to the spinal cord that resulted in neurogenic bladder, which had caused recurrent urinary tract infections. He underwent a left nephrectomy for a renal cell carcinoma (T3N0M0) four years before the admission, and was in remission, with mild renal impairment.

At the time of his hospital admission, he denied chronic alcohol intake, and his medication, which included pregabalin and amitriptyline, had not changed in the preceding weeks. A physical examination showed petechiae and palpable spleen (2 cm below the costal edge) without lymphadenopathies. Laboratory parameters indicated severe thrombocytopenia (platelet count $8 \times 10^9/L$), a leukocyte count of $3 \times 10^9/L$ (neutrophils $1.6 \times 10^9/L$; lymphocytes $1.3 \times 10^9/L$) and mild-moderate regenerative macrocytic anemia (hemoglobin 110 g/L, MCV 110 fl, and 95×10^9 absolute reticulocyte count), with normal peripheral blood smear morphology except for the reduced number of platelets. The direct antiglobulin test (DAT) was positive and warm IgG autoantibody was identified. Samples were negative for antinuclear antibodies (ANAs). The level of creatinine was slightly elevated (1.34 mg/dL). All other laboratory measurements, including those of B12 vitamin, folic acid, basic coagulation, LDH, and liver function tests were normal. Tests for hepatitis B and C, and HIV virus were negative.

In the BM study the aspiration smear and biopsy section showed hypercellularity, with an almost complete absence of megakaryocytes, and the presence of moderate erythroid hyperplasia, normal granulocyte precursors without dysplastic features, and a raised number of plasma cells (Figure 1). An increase in the lymphocyte count was observed in some areas, but flow cytometry ruled out clonality and paroxysmal nocturnal hemoglobinuria. The study was repeated in the contralateral iliac crest spine, giving similar results. Cytogenetic studies of the BM showed a normal karyotype (46 XY).

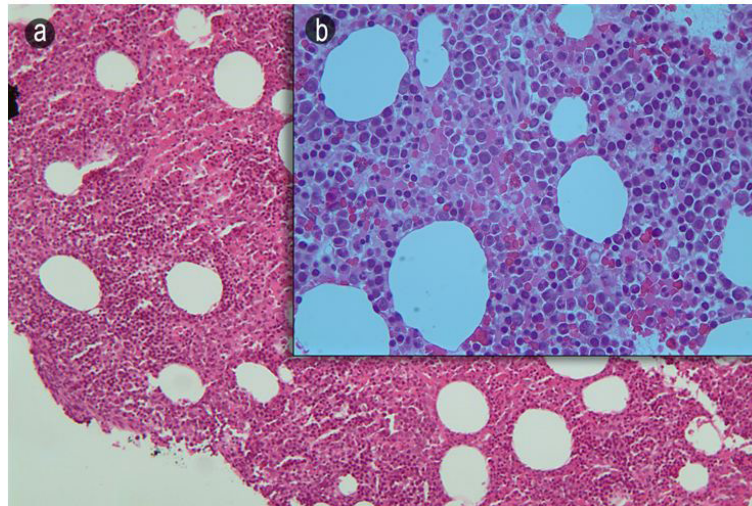


Figure 1: Detail of bone marrow aspirate clot section, HE stain, 20X (A) and 40X (B) magnification, showing normal cellularity with absence of megakaryocytes and increased number of plasma cells

The patient was first treated with IV gamma globulins (30 g/day x 5 days) and prednisone (90 mg/day), which produced a slight, temporary improvement; the petechiae persisted but there was no new bleeding. A few days after starting this treatment, the platelet count reached $24 \times 10^9/L$ and the DAT became negative. Azathioprine was added for one month but then suspended due to the appearance of neutropenia without response in the platelet count.

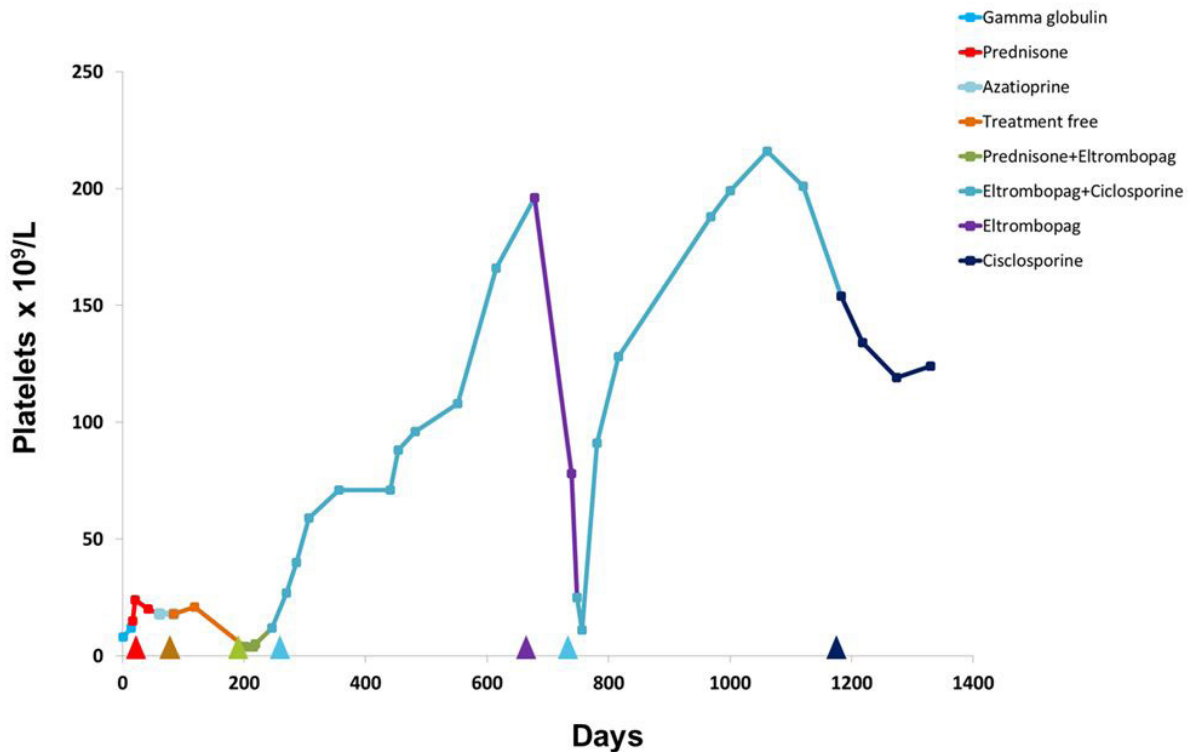


Figure 2: Changes in platelet counts after successive treatments during follow-up

Six months after diagnosis, the platelet count decreased again to $4 \times 10^9/L$ and a new BM examination was done, which gave similar results. The response to all previously used agents, alone or in combination, was not acceptable, so we decided to use EPAG because the patient had only one kidney and suffered mild renal insufficiency and was at risk of nephrotoxicity through the use of calcineurin inhibitors. We administered EPAG (50 mg/day, subsequently increased to 100 mg/day) plus prednisone. The

petechiae disappeared but the platelet count did not improve, so two months after EPAG was commenced, we added CsA (300 mg/day, with a target nadir level serum of 150 µg/mL). When these two drugs were combined, platelets returned to their baseline level (Figure 2). Fourteen months later, the platelet level was still normal so CsA therapy was discontinued and the EPAG dose was reduced. Three months later, the platelet number had dropped again so CsA therapy was restarted and the EPAG dose was increased. After one further month with the two-drug combination, the platelet count had normalized again. After one year with this treatment, we decided to suppress EPAG but maintain CsA and, six months later, the number of platelets was maintained (Figure 2). No morphological alterations were observed in peripheral blood, and renal and liver functions remained close to baseline levels throughout the treatment.

Discussion and Conclusions

The incidence of AAT is unknown, and so may be higher than previously reported. Differential diagnosis is widespread and some cases can be misdiagnosed as immune thrombocytopenia (ITP) because these conditions are clinically indistinguishable, only differing with respect to BM [1]. The possibility of AAT should be seriously considered when the level of megakaryocytes is decreased but there is no bone marrow hypocellularity, whereas ITP is more likely when there is megakaryocytic hyperplasia in the BM. In others cases, AAT can be confused with aplastic anemia (AA) because of the “patchy” appearance of the BM that is sometimes observed in this condition. A reduced level, or the complete absence, of megakaryocytes and the presence of areas showing increased BM cellularity may be observed for both diseases, but a BM biopsy can differentiate them. It is important to distinguish these conditions because the therapeutic approaches required are different [10]. BM cellularity in our patient showed erythroid hyperplasia with good reticulocyte response and normal values of the other series, ruling out a diagnosis of AA and favoring one of AAT. Our patient also had splenomegaly and was IgG DAT-positive, as reported in another case [3].

The pathogenesis of AAT is uncertain. Most of the cases reported have been associated with autoimmune processes [1]. Several potential mechanisms have been postulated for the immune-mediated suppression of thrombopoiesis, including cell-mediated immunity, antithrombopoietin IgG antibodies (anti-TPO) and antibodies against its receptor on megakaryocytes (cMpl) [11-13]. Anti-TPO and anti-cMpl autoantibodies may both functionally inhibit the hormonal stimulation of megakaryocytic progenitors by thrombopoietin (TPO). The autoimmunity of our patient was affected (DAT-positive with regenerative anemia), which led us to suspect this mechanism to be one of the causes of the thrombocytopenia, breakdown of platelets in the peripheral blood and the inhibition of megakaryocyte production, as reported previously [14]. Some drugs have been involved, either by antibody production against platelets or by suppressing thrombopoiesis but our patient had neither changed the dose of their medication nor started taking new ones [2].

AAT standard treatment guidelines have not yet been established and a wide range of therapies is used. Most patients with AAT respond to immunosuppressants. The success of steroids as monotherapy, often in a front-line setting, is limited. Responses to azathioprine, rituximab, antithymocyte globulin and CsA have been reported [3,15-17]. CsA, alone or in combination, is the most commonly used medication and may be considered the drug of choice for AAT. Some patients are treated by allogeneic transplantation [18]. TSAs such as the nonpeptide mimetic EPAG, which is orally available, have also been used. This is a synthetic molecule that has been shown to stimulate TPO-dependent cell lines via the JAK2 and STAT signaling pathways, inducing proliferation, megakaryocyte differentiation, and platelet production. The mechanism of action of EPAG in the context of BM failure is unclear but it has been suggested that it is may be able to bypass the blockade caused by anti-TPO receptor (c-Mpl antibodies) in thrombopoiesis [19]. It interacts with the transmembrane portion of the TPO receptor in megakaryocytes and hematopoietic stem cells, rather than at the site of native TPO binding. In our case, the patient received EPAG alone for 55 days, and although the disappearance of the petechiae indicated a clinical improvement, the platelet count did not increase. Only when EPAG was combined with CsA did the platelet count begin to recover. In addition, when the administration of CsA was suspended, the platelet count dropped again. Our patient is currently being treated with CsA as a single agent and his platelet count has continued to be adequate six months after stopping EPAG.

The cause of the response can never be ascertained because the patient has multiple diseases and has undergone various therapeutic interventions with splenomegaly, but, based on other published reports and the case described here, we think that the use of both drugs for treating AAT, at least at the beginning of treatment, as for aplastic anemia, may help ensure a good response. Continuous exposure to EPAG is probably not necessary to maintain the response. Indeed, continuous exposure to TPO mimetics increases the possibility of clonal evolution [9,20].

References

1. Agarwal N, Spahr JE, Werner TL, Newton DL, Rodgers GM (2006) Acquired amegakaryocytic thrombocytopenic purpura. *Am J Hematol* 81: 132-5.
2. Patel M, Kalra A, Surapaneni R, Schwarting R, Devereux L (2004) Acquired amegakaryocytic thrombocytopenia in a patient with occupational chemical exposure. *Am J Ther* 21: 17-20.
3. Her MY, Kim TH, Chang HK, Lee WS, Yoo DH (2007) Successful treatment of acquired amegakaryocytic thrombocytopenia with cyclosporine in adult onset Still's disease. *Rheumatol Int* 27: 295-8.
4. Bhattacharyya J, Kumar R, Tyagi S, Kishore J, Mahapatra M, et al. (2005) Human parvovirus B19-induced acquired pure amegakaryocytic thrombocytopenia. *Br J Haematol* 128: 128-9.

5. King JA, Elkhalfi MY, Latour LF (1997) Rapid progression of acquired amegakaryocytic thrombocytopenia to aplastic anemia. *South Med J* 90: 91-4.
6. Chaudhary UB, Eberwine SF, Hege KM (2004) Acquired amegakaryocytic thrombocytopenia purpura and eosinophilic fasciitis: a long relapsing and remitting course. *Am J Hematol* 75: 146-50.
7. Cela I, Miller IJ, Katz RS, Rizman A, Shammo JM (2010) Successful treatment of amegakaryocytic thrombocytopenia with eltrombopag in a patient with systemic lupus erythematosus (SLE). *Clin Adv Hematol Oncol* 8: 806-9.
8. Shigekiyo T, Sekimoto E, Shibata H, Ozaki S, Fujinaga H, et al. (2005) Treatment of acquired amegakaryocytic thrombocytopenic purpura with romiplostin. *Platelets* 26: 504-6.
9. Desmond R, Townsley DM, Dumitriu B, Olnes MJ, Scheinberg P, et al. (2014) Eltrombopag restores trilineage hematopoiesis in refractory severe aplastic anemia that can be sustained on discontinuation of drug. *Blood* 123: 1818-25.
10. Scheinberg P, Young NS (2012) How I treat acquired aplastic anemia. *Blood* 120: 1185-96.
11. Gewirtz AM, Sacchetti MK, Bien R, Barry WE (1986) Cell-mediated suppression of megakaryocytopoiesis in acquired amegakaryocytic thrombocytopenic purpura. *Blood* 68: 619-26.
12. Shiozaki H, Miyawaki S, Kuwaki T, Hagiwara T, Kato T, et al. (2000) Autoantibodies neutralizing thrombopoietin in a patient with amegakaryocytic thrombocytopenic purpura. *Blood* 95: 2187-8.
13. Kuwana M, Okazaki Y, Kajihara M, Kaburaki J, Miyazaki H, et al. (2002) Autoantibody to c-Mpl (thrombopoietin receptor) in systemic lupus erythematosus: relationship to thrombocytopenia with megakaryocytic hypoplasia. *Arthritis Rheum* 46: 2148-59.
14. Chang M, Nakagawa PA, Williams SA, Schwartz MR, Imfeld KL, et al. (2003) Immune thrombocytopenic purpura (ITP) plasma and purified ITP monoclonal autoantibodies inhibit megakaryocytopoiesis in vitro. *Blood* 102: 887-95.
15. Chang H, Tang TC (2011) Successful treatment of amegakaryocytic thrombocytopenia with azathioprine. *Acta Haematol* 126: 135-7.
16. Deeren D, Dorpe JV (2010) Effective use of rituximab for acquired amegakaryocytic thrombocytopenia. *Am J Hematol* 85: 977-8.
17. Brown GE, Babiker HM, Cantu CL, Yeager AM, Krishnadasan R (2014) "Almost bleeding to death": The conundrum of acquired amegakaryocytic thrombocytopenia. *Case Rep Hematol* 2014: 806541.
18. Lonial S, Bilodeau PA, Langston AA, Lewis C, Mossavi-Sai S, et al. (1999) Acquired amegakaryocytic thrombocytopenia treated with allogeneic BMT: a case report and review of the literature. *Bone Marrow Transplant* 24: 1337-41.
19. Lown R, Rhodes E, Bosworth J, Shannon MS, Stasi R (2010) Acquired amegakaryocytic thrombocytopenia: potential role of thrombopoietin receptor agonists. *Clin Adv Hematol Oncol* 8: 809-12.
20. Townsley DM, Scheinberg P, Winkler T, Desmond R, Dumitriu B, et al. (2017) Eltrombopag added to standard immunosuppression for aplastic anemia. *N Engl J Med* 376: 1540-50.

Submit your next manuscript to Annex Publishers and benefit from:

- ▶ Easy online submission process
- ▶ Rapid peer review process
- ▶ Online article availability soon after acceptance for Publication
- ▶ Open access: articles available free online
- ▶ More accessibility of the articles to the readers/researchers within the field
- ▶ Better discount on subsequent article submission

Submit your manuscript at

<http://www.annepublishers.com/paper-submission.php>