

Jugular Foramen Schwannoma Revealed By Unilateral Deafness

Benbakh M*, Adnane C, Zouak A, Sofiane N, Rouadi S, Abada R, Roubal M and Mahtar M

Department of ENT, 20 Aout hospital, Ibn Rochd university hospital, Casablanca, Morocco

*Corresponding author: Benbakh M, Department of ENT, 20 Aout hospital, Ibn Rochd university hospital, Casablanca, Morocco, E-mail: mohamedbenbakh@gmail.com

Citation: Benbakh M, Adnane C, Zouak A, Sofiane N, Rouadi S, et al. (2014) Jugular foramen schwannoma revealed by unilateral deafness. J Case Rep Stud 3(3): 301. doi: 10.15744/2348-9820.3.301

Received Date: November 29, 2014 Accepted Date: June 05, 2015 Published Date: June 09, 2015

Abstract

Jugular foramen schwannomas arising from cranial nerves IX, X, and XI are uncommon pathological conditions, slowly growing benign tumors that constitute approximately 2.9 to 4% of all intracranial schwannomas [1,2]. Jugular foramen schwannomas represent 10-30% of all tumors observed around the jugular foramen [3,4]. The standard primary treatment for jugular foramen schwannomas is total surgical removal [5,6]. However, there is significant morbidity that results from extensive surgery and complex anatomical location. In the literature, there are a few published studies on radiosurgery for jugular foramen schwannomas [7-10]. The present study report a 28-year-old woman diagnosed with jugular foramen schwannomas who underwent gamma knife radiosurgery (GKS) in the IBN ROCHD university hospital of Casablanca, Morocco.

Case report

A 48-year-old woman presented with progressive right-sided hearing loss, chronic dysphonia and tinnitus. These signs were associated with chronic headache and dizziness for two years. On physical examination, the eardrums were normal. There was a right facial nerve dysfunction classified grade III according to House Brackmann grading system. Oral examination found a left side deviating uvula (curtain sign), tongue weakness with mild atrophy and abolition of gag reflex. Cervical examination showed a right shoulder weakness without palpable cervical mass. Laryngeal endoscopic exam found right vocal cord paralysis. There were no other significant cranial nerve findings. A finger-to-nose examination showed mild ataxia of the right upper limb. The gait was normal. An audiogram demonstrated a 60 dB sensorineural hearing loss. The stapedius reflex was absent. A CT scan was performed and found an enlargement of the jugular foramen and moderate enhancement with contrast medium (Figure 1). Magnetic resonance imaging (MRI) showed an isointense tumor on T1 weighted images (WI), hyperintense on T2 WI and enhance with gadolinium, this tumor extended to the internal auditory meatus (Figure 2). The patient was treated with GKS with a good clinical evolution.

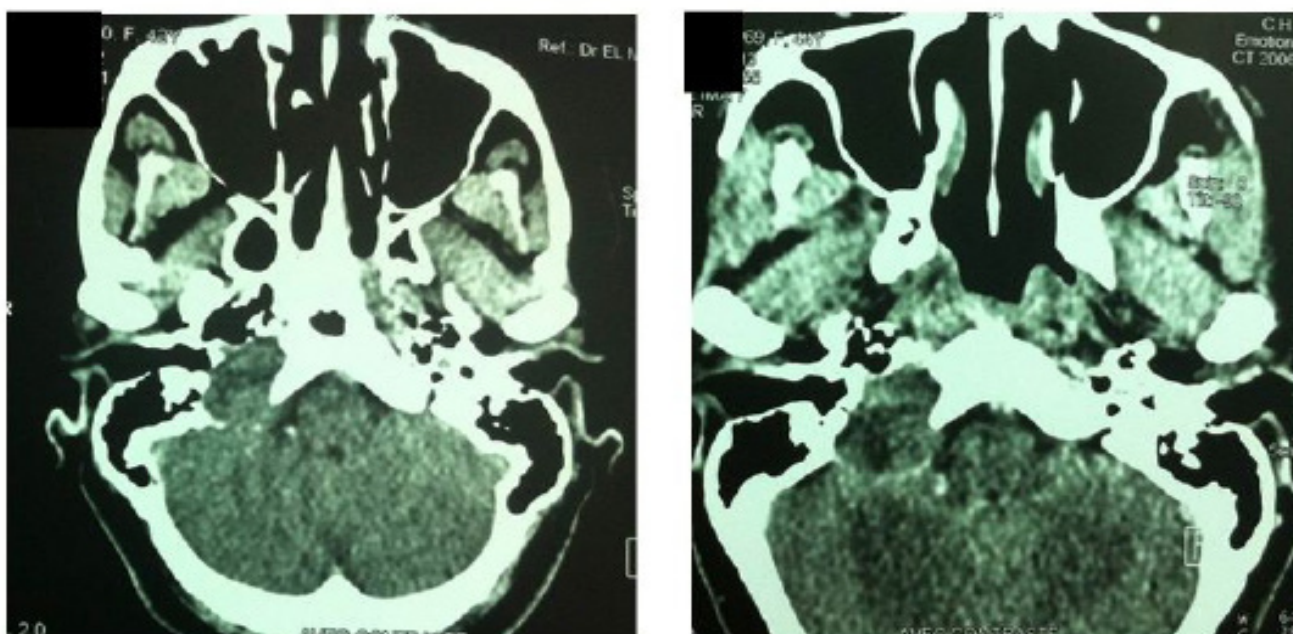


Figure 1: Tumor swarming over the jugular, this mass became hyperdense after injection of contrast

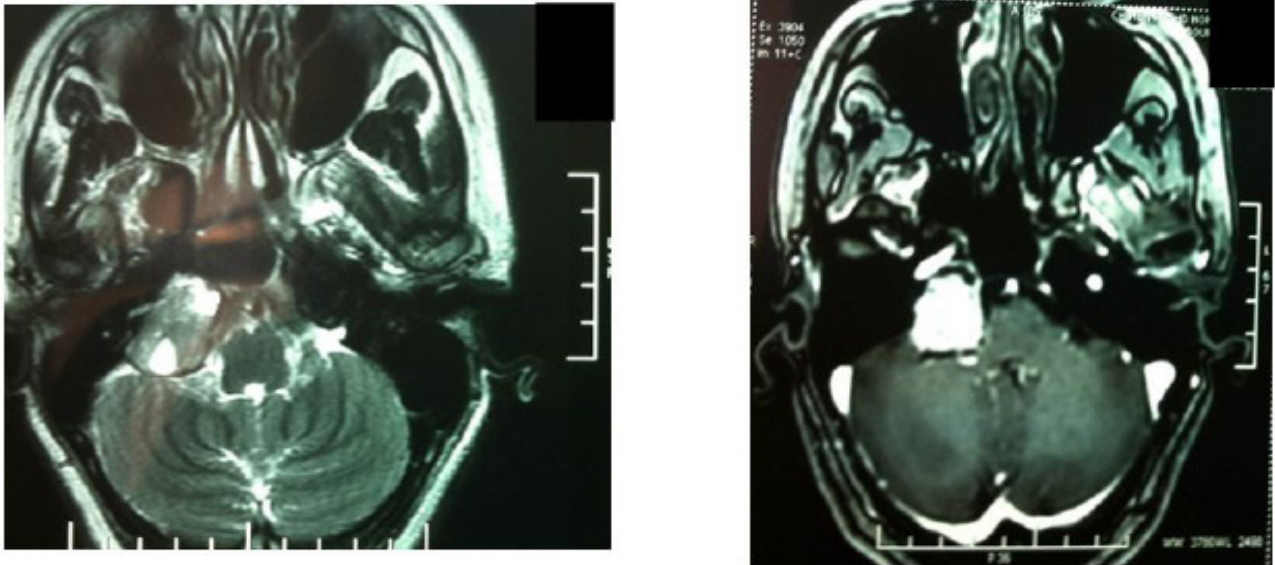


Figure 2: MRI appearance of a schwannoma of mixed nerves

Discussion

The jugular foramen, located between the temporal bone laterally and the occipital bone medially, transmits the internal jugular vein, posterior meningeal artery, the IXth, Xth, and XIth cranial nerves and the inferior petrosal sinus.

A variety of neoplasms can arise within or around the jugular foramen. These include glomus tumors, the most common tumor, followed by schwannomas. In addition, meningiomas, chordomas, carcinomas, sarcomas, and neuroblastomas have been found in this area [11].

Jugular foramen schwannomas are rare, they commonly occur between the third and sixth decades of life, mainly in women [1,2,12-14]. The nerve of origin for the tumor is often identified only during surgery and the exact nerve of origin remains for most part unknown [15]. The most common symptom was hearing loss, followed by lower cranial nerve dysfunction. This was true in the present case report. The symptoms were very complete, so the decision was to perform radiological explorations (CT scan and MRI) without other hearing tests such auditory brainstem response (ABR) or otoacoustic emissions testing (OAE).

Jugular foramen schwannomas may originate from cisternal, foraminal, or extracranial portion of the nerves. Tumors originating from cisternal part grow more in the intracranial space and cerebellopontine angle; tumors originating from the foraminal portion predominantly expand the bone in the jugular foramen; and tumors originating from the extracranial part present with major extracranial growth [6,12,15-17]. For these tumors, many classifications have been developed, depending on their localization and radiologically extension [15,18]. Kaye's modified classification based on the findings from MRI is the most used [12]. Tumors that were primarily intracranial with only minor extension into bone were classified as type A; those that were located mainly within bone with or without an intracranial component were type B; those that were primarily extracranial with only minor extension into bone or the posterior fossa were type C. Type D (dumbbell-shaped) for tumors comprised lesions with significant intra- and extracranial portions.

CT scan orients the diagnosis by providing adequate data about the enlargement of the jugular canal and demonstrates either bone infiltration. MRI is only the tool to diagnose and to differentiate it from the other jugular foramen tumors. The imaging characteristics of jugular foramen schwannomas are usually iso- or hypointense on T1 WI and iso- or hyperintense on T2 WI and enhance with gadolinium [19].

Surgical resection is the standard procedure in patients with jugular foramen schwannomas [5,6]. However, there is significant morbidity that results from extensive surgery and complex anatomical location. There had been many approaches to this lesion: suboccipital, retrosigmoid, translabyrinthine, or infratemporal approach, but no general consensus has been reached. According to the literature, there are a few published studies on radiosurgery for jugular foramen schwannomas [7-10]. However, the tumor control rate for these tumors following GKS ranges between 96 and 100%, and the tumor shrinkage rate ranges between 47 and 52% [7,9,10,20]. This method is useful for residual tumors and also in the initial treatment of small tumors, especially when they are less than 3 cm and there is no lower cranial nerve palsy [20].

In this case report, the use of GKS for a jugular foramen schwannoma type C has a good outcome with no complication comparing to surgical resection.

Conclusion

Jugular foramen schwannoma are very rare tumors, and usually seen in adults. It can cause high intracranial pressure symptoms and cranial nerve abnormalities such as hearing loss, speech and swallowing disabilities. The surgery is challenging and associated with morbidity like cranial nerve palsy and cerebrospinal fluid (CSF) leak, radiation therapy or gamma knife can be preferred in uncomplicated small lesions. Surgery can be reserved for larger tumors.

References

1. Tan LC, Bordi L, Symon L, Cheesman AD (1990) Jugular foramen neuromas: a review of 14 cases. *Surg Neurol* 34: 205-11.
2. Samii M, Babu RP, Tatagiba M, Sepehrnia A (1995) Surgical treatment of jugular foramen schwannomas. *J Neurosurg* 82: 924-32.
3. Ramina R, Maniglia JJ, Fernandes YB, Paschoal JR, Pfeilsticker LN, et al. (2005) Tumors of the jugular foramen: diagnosis and management. *Neurosurgery* 57: 59-68.
4. Tekkök IH, Ozcan OE, Turan E, Onol B (1997) Jugular foramen meningioma. Report of a case and review of the literature. *J Neurosurg* 41: 283-92.
5. Lee SK, Park K, Kong DS, Cho YS, Baek CH, et al. (2001) Surgical tactics and outcome of treatment in jugular foramen schwannomas. *J Clin Neurosci* 8: S32-9.
6. Sarma S, Sekhar LN, Schessel DA (2002) Nonvestibular schwannomas of the brain: a 7-year experience. *Neurosurgery* 50: 437-48.
7. Kida Y, Kobayashi T, Tanaka T, Oyama H, Niwa M (1995) A new strategy for the treatment of jugular foramen tumors using radiosurgery. *No Shinkei Geka* 23: 671-5.
8. Mabanta SR, Buatti JM, Friedman WA, Meeks SL, Mendenhall WM, et al. (1999) Linear accelerator radiosurgery for nonacoustic schwannomas. *Int J Radiat Oncology Biol Phys* 43: 545-8.
9. Pollock BE, Foote RL, Stafford SL (2002) Stereotactic radiosurgery: the preferred management for patients with nonvestibular schwannomas? *Int J Radiat Oncol Biol Phys* 52: 1002-7.
10. Pollock BE, Kondziolka D, Flickinger JC, Maitz A, Lunsford LD (1993) Preservation of cranial nerve function after radiosurgery for nonacoustic schwannomas. *Neurosurgery* 33: 597-601.
11. Maniglia AJ, Chandler JR, Goodwin WJ, Pantier JC (1979) Schwannomas of the parapharyngeal space and jugular foramen. *Laryngoscope* 89: 1405-14.
12. Kaye AH, Hahn JE, Kinney SE, Hardy RW, Bay JW (1984) Jugular foramen schwannoma. *J Neurosurg* 60: 1045-53.
13. Wang CC, Liu A (1995) Surgical management of nonglomus tumors of the jugular foramen *Operative Neurosurgical Technique-Indications, Methods, and Results* (3rd edn) Vol 1 Philadelphia: WB Saunders, USA 865-73.
14. Yoo H, Jung HW, Yang HJ (1999) Jugular foramen schwannomas : surgical approaches and outcome of treatment. *Skull Base Surg* 9: 243-52.
15. Sanna M, Bacciu A, Falcioni M, Taibah A (2006) Surgical management of jugular foramen schwannomas with hearing and facial nerve function preservation: a series of 23 cases and review of the literature. *Laryngoscope* 116: 2191-204.
16. Carvalho GA, Tatagiba M, Samii M (2000) Cystic schwannomas of the jugular foramen: clinical and surgical remarks. *Neurosurgery* 46: 560-6.
17. Kadri PA, Al-Mefty O (2004) Surgical treatment of dumbbell-shaped jugular foramen schwannomas. *Neurosurg Focus* 17: E9.
18. Tomio S, Takakura K (1991) Twelve cases of jugular foramen neurinoma. *Skull Base Surg* 1: 152-60.
19. Eldevik OP, Gabrielsen TO, Jacobsen EA (2000) Imaging findings in schwannomas of the jugular foramen. *AJNR Am J Neuroradiol* 21: 1139-44.
20. Muthukumar N, Kondziolka D, Lunsford LD, Flickinger JC (1999) Stereotactic radiosurgery for jugular foramen schwannomas. *Surg Neurol* 52: 172-9.

Submit your next manuscript to Annex Publishers and benefit from:

- Easy online submission process
- Rapid peer review process
- Online article availability soon after acceptance for Publication
- Open access: articles available free online
- More accessibility of the articles to the readers/researchers within the field
- Better discount on subsequent article submission

Submit your manuscript at
<http://www.annexpublishers.com/paper-submission.php>